

Received: 2012.07.07  
Accepted: 2012.10.09

## Rib fracture: Different radiographic projections

Abed-Al Nasser Assi<sup>1</sup>, Yasser Nazal<sup>2</sup>

<sup>1</sup> Arab-American University, Palestine

<sup>2</sup> AL-Razi Hospital, Palestine

Author's address: Abed Al Nasser Assi, Akaba, Jenin, Palestine, e-mail: aassi@aauj.edu

### Summary

**Background:**

Rib fracture is the most common thoracic injury. It is thought to be present in 10% of all traumatic injuries and in almost 40% of patients who sustained severe non-penetrating trauma. There are 12 pairs of ribs. This study reviews various methods of acquisition and reconstruction of radiographic images of traumatic rib fractures in order to determine the optimal views and to simplify rib fracture diagnostics.

**Material/Methods:**

Eight different plain radiography pictures of ribs were performed with the patient in an erect position. The following projections were obtained in sequence: oblique at 45° or 30° angle on inspiration, oblique at 45° or 30° angle on expiration as well as 45° and 39° projections during slow and fast breathing. All radiographic examinations were performed using a Philips three-phase scanner installed at the Al- Razi Hospital in Jenin, Palestine.

**Results:**

The results demonstrate that the 45° antero-posterior oblique projection performed on expiration is recommended for diagnostics and interpretation of traumatic rib fractures.

**Conclusions:**

Conclusion emerging from this study are such that for a 45° oblique view on expiration is recommended for radiographic imaging of patients with clinical signs of fracture, e.g. evaluation of lower rib fractures, while 45° oblique view during fast breathing is recommended for suspected upper rib fractures.

**Key words:**

chest • ribs • expirations • inspirations • slow breathing • fast breathing

**PDF file:**

<http://www.polradiol.com/fulltxt.php?ICID=883623>

### Background

Rib fracture is the most common thoracic injury and is thought to be present in 10% of all traumatic injuries and in almost 40% of patients who sustain severe non-penetrating trauma [1,2]. There are 12 pairs of ribs attached to the vertebra (backbone) at the back and 10 of which are attached to the sternum by cartilage (breastbone) at the front. Ribs serve as protection for vital organs of chest cavity such as the heart, lungs, liver, and spleen.

Rib fractures typically affect the fifth through ninth rib. This may be due to the fact that the shoulder girdle offers relative protection to the upper ribs while lower ribs are relatively mobile and may deflect before fracturing [1]. Neither clinical examination nor radiography is ideal for the diagnosis of rib fractures. While rib fractures can produce significant morbidity, the diagnosis of associated complications such as pneumothorax, hemothorax,

pulmonary contusion, flail chest, pneumonia, vascular and nerve damage (especially with trauma to the upper chest or ribs 1–3). Abdominal organ injury is common [3] (most often involves liver, spleen, kidneys, and diaphragm.[4]), particularly with trauma to the lower thorax or lower ribs.

**Causes:** Rib fractures can occur without direct trauma (patient complains of symptoms after persistent coughing) and during participation in various sports such as rowing and golf, often in elite athletes. These fractures can also occur as a result of various diseases such as cancer or infections. Causes vary from a fall or a blow to the chest to hard coughing or sneezing. Children have more flexible chest walls than adults do, so their ribs are more likely to bend than to break. Rib fractures in children indicate severe thoracic injuries such as pulmonary contusion. Rib fractures in children are most often caused by car accidents. It has been observed that rib fractures are more common in teenagers participating in contact sports such as football or hockey.

**Signs/Symptoms:** Patient with rib fracture suffers from pain, especially on inspiration or during movement. Other symptoms include tenderness and shallow breathing. A portion of thoracic wall moves separately from the rest of the chest (flail chest). There is a grating sound during breathing or movement. Rib fractures may also indicate more serious injuries in elderly people. Patients also exhibit symptoms of anxiety, restless or fear. They may complain of headache, feel dizzy, tired or sleepy.

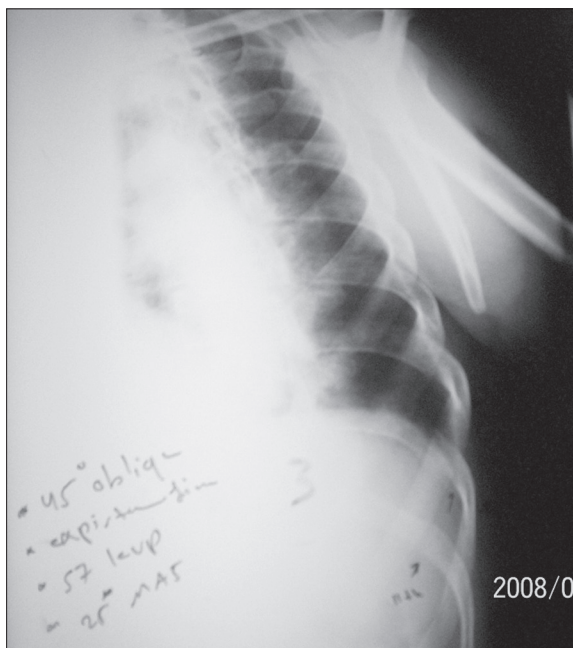Chest x-ray remains the most effective method of diagnosing rib fractures. Approximately 25% of them do not show on x-ray and are diagnosed upon physical examination. Rib fractures are problematic because normal breathing causes pain. Griffith et al [5] examined radiographic studies (chest radiography plus a single oblique projection) in 50 patients and found that radiographs detected only 8 of 83 (10%) rib fractures diagnosed by ultrasonography and were positive in only 6 of 39 patients with demonstrated fractures. Radiographic identification of rib fracture can help prevent complications such as atelectasis and is particularly important in patients with comorbidities such as chronic obstructive pulmonary disease, cardiac disease, hepatic disease, renal disease, dementia and coagulopathy [6]. It can also facilitate pain management, particularly in patients with undiagnosed fractures and long-standing, refractory pain.

Plain radiography of the chest with or without oblique views and optimized by the technician for bony details ("bone technique") has historically been the test of choice for diagnostic imaging. However, it may miss up to 50% of fractures [7]. Furthermore, it is not sensitive for costal cartilage [8] or stress fractures. Despite these limitations, plain radiography is vitally important in diagnosing complications and associated injuries such as a pneumothorax, hemothorax, pulmonary contusion, pneumomediastinum, or pneumoperitoneum. Additionally, widened mediastinum may indicate aortic injury. Currently, a standard chest x-ray is often the initial study of choice in evaluation of chest pain and in cases of minor blunt trauma. If rib fractures are suspected clinically, performing a rib series can be of benefit. A rib series consists of a marker placed over the region of interest, oblique views, and optimization of the radiograph by the technician to highlight bony detail, guiding clinical judgment on rib radiography.

The aim of this study was to perform rib radiography from various projections in order to find the best view for rib examination and to assess their clinical applications in acute traumatic lesions and their chronic sequelae.

## Material and Methods

A 53-year-old male was admitted to the emergency room after a road traffic accident. Among other things, he complained of left-sided chest pain. On physical examination he had local tenderness over lateral thorax with some superficial swelling and bruising. This patient underwent imaging to determine if there had been a rib fracture. Which imaging study would be most appropriate? On evaluation, he was found to have splenic injury and fractures of left ribs.



**Figure 1.** Shows 45° oblique view of the ribs (fractures of the 8<sup>th</sup>, 9<sup>th</sup>, 10<sup>th</sup> and 11<sup>th</sup> rib).

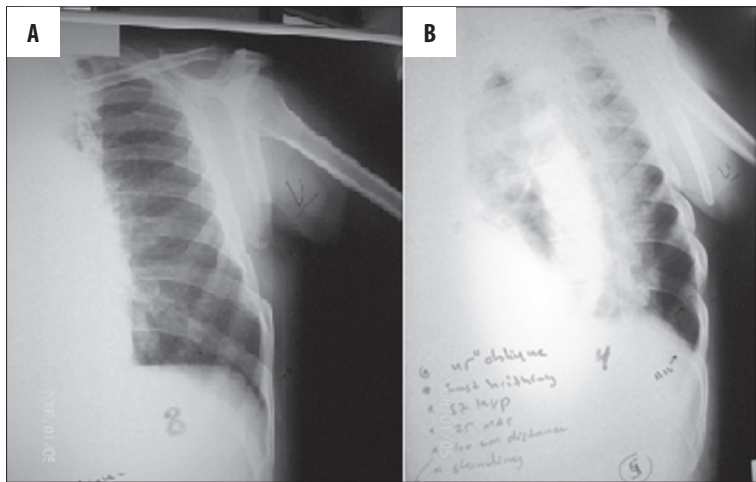
This article outlines the use of various imaging techniques in evaluation of suspected rib fractures and recommends a management approach. The subject had x-ray pictures taken from eight different views in order to find the best one for the diagnosis and evaluation of rib fractures. These views included rib projections on inspiration, on expiration and during slow and fast breathing. Views were obtained sequentially at 30° and 45° angles in anterior oblique position. All radiographic-examinations were performed with a Philips three-phase scanner installed in Al-Razi Hospital in Jenin, Palestine.

Patient was in an erect position, rotated at 30° and subsequently 45°. Affected side was directed toward IR, ipsilateral arm was elevated above the head, other arm extended down and away from the thorax, CR was perpendicular to IR, centred to T7. Scan parameters were KVP=57; mAs=25, SID=100 cm.

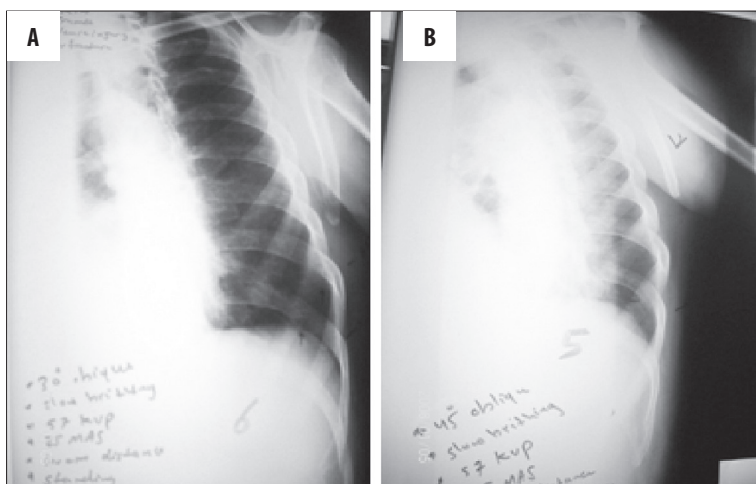
## Results

Imaging diagnostics indicate that 45° antero-posterior oblique projection obtained during inspiration is recommended to simplify rib trauma evaluation (Figure 1). Figure shows fractures of various ribs (8<sup>th</sup>, 9<sup>th</sup>, 10<sup>th</sup> and 11<sup>th</sup>). Other projections: 30° antero-posterior oblique, 45° antero-posterior oblique during fast breathing and 30° antero-posterior oblique during slow breathing show rib fractures (8<sup>th</sup>, 9<sup>th</sup>, 10<sup>th</sup>) in different views. Fracture of the 11<sup>th</sup> rib was best demonstrated in 45° oblique view obtained on expiration and 45° oblique view obtained during fast breathing.

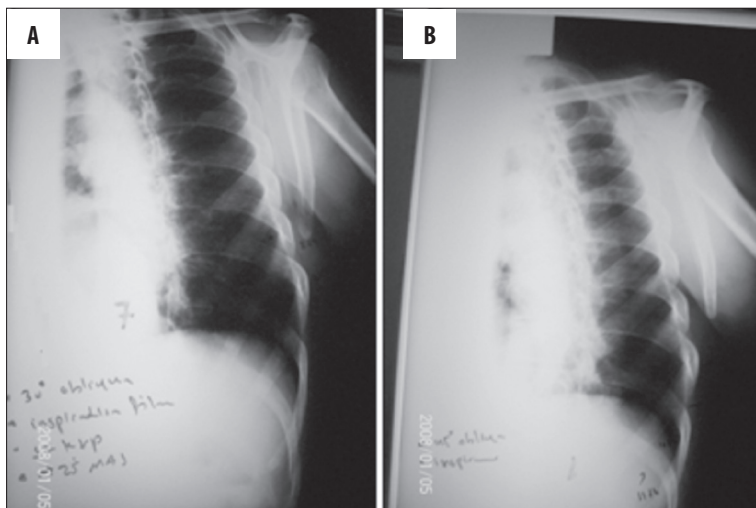
Sometimes, if the plain radiograph is normal, symptoms may warrant further investigation. Studies have shown that if a rib fracture is suspected and rib x-ray picture is normal, then patient should have an oblique radiogram



**Figure 2.** Oblique radiographic image at 30° (A) and at 45° (B) view obtained during fast breathing shows acute 8<sup>th</sup>, 9<sup>th</sup>, 10<sup>th</sup> and 11<sup>th</sup> rib fractures.



**Figure 3.** Oblique radiographic image at 30° (A) and at 45° (B) view obtained during slow breathing shows acute 8<sup>th</sup>, 9<sup>th</sup> and 10<sup>th</sup> rib fractures.



**Figure 4.** Oblique radiographic image at 30° (A) and at 45° (B) view performed on inspiration shows acute 8<sup>th</sup>, 9<sup>th</sup> and 10<sup>th</sup> rib fractures 5.

performed during fast breathing whenever possible, as fast breathing may stimulate rib movement during examination, simplifying the diagnostics. (Figure 2).

In addition, several abnormalities related to rib fractures were detected on different radiographic views: 45° oblique projection during slow breathing; 30° oblique projection during slow breathing (Figure 3)

Views obtained from 45° oblique projection performed during inspiration; 30° oblique projection performed during inspiration (Figures 4)

### Discussion

In general, the majority of cases of chest trauma rib radiography is required, as the rate of associated injury in patients

with rib fractures is high [7,9]. Radiographic confirmation of rib fracture is indicated in order to avoid potentially severe complications such as pneumothorax, hemothorax, pulmonary contusion, or pneumonia and can help prevent complications such as atelectasis. A simple of radiographic examination of the ribs is sufficient to solve radiographically demonstrable clinical problem. However, in selected, difficult cases, CT can be useful and may add a great deal of information crucial for patient treatment [10]. In this particular case of trauma patient, a standard chest x-ray was initially taken to evaluate chest pain and a rib series was obtained when rib fractures were suspected. A rib series consisting of a marker placed over the region of interest, oblique views (30° and 45°) on inspiration, on expiration, as well as during slow and fast breathing was performed in order to identify the best view. It was concluded that the 45° oblique projection was the best view from these series. This may be due to the fact that 45° oblique views eliminate the superimposition of the spleen and the ribs, while expiration may affect image contrast as the lung volume decreases, eliminating the superimposition of the lung.

Knowing the number of fractured ribs may also influence other treatment decisions, such as whether to transfer the patient to a trauma center: examination revealed four rib fractures (8<sup>th</sup>, 9<sup>th</sup>, 10<sup>th</sup>, and 11<sup>th</sup> ribs) in a 45° oblique view during expiration and in a 45° oblique view acquired during fast breathing. Fracture of the 11<sup>th</sup> rib was shown in a radiogram obtained during fast breathing. This may be due to the fact that rib movements were stimulated during radiographic examination, which allowed better visualization of the fracture in comparison to examination during slow breathing.

## Conclusions

Conclusion emerging from this study are such that for a 45° oblique view on expiration is recommended for radiographic imaging of patients with clinical signs of fracture, e.g. evaluation of lower rib fractures, while 45° oblique view during fast breathing is recommended for suspected upper rib fractures.

## References:

1. Alkadhhi H, Wildermuth S, Marincek B et al: Accuracy and time efficiency for the detection of thoracic cage fractures: volume rendering compared with transverse computed tomography images. *J Comput Assist Tomogr*, 2004; 28(3): 378–85
2. Bansidhar BJ, Lagares-Garcia JA, Miller SL: Clinical rib fractures: are follow-up chest X-rays a waste of resources? *Am Surg*, 2002; 68(5): 449–53
3. Bansidhar BJ, Lagares-Garcia JA, Miller SL: Clinical rib fractures: are follow-up chest x-rays a waste of resources? *Am Surg*, 2002; 68: 449–53
4. Schwartz SI: Principles of surgery, 3<sup>rd</sup> ed. New York: McGraw Hill, 1979: 649–65
5. Griffith JE, Rainer TH, Ching AS et al: Sonography compared with radiography in revealing acute rib fracture. *AJR*, 1999; 173(6): 1603–9
6. Moloney TU, Rogers DE: A different view of the contentious debate over costs. *N Eng J Med*, 1979; 301: 1413–19
7. Bergeron E, Lavoie A, Clas D et al: Elderly trauma patients with rib fractures are at greater risk of death and pneumonia. *J Trauma*, 2003; 54: 478–85
8. Kara M, Dikmen E, Erdal HH et al: Disclosure of unnoticed rib fractures with the use of ultrasonography in minor blunt chest trauma. *Eur J Cardiothorac Surg*, 2003; 24: 608–13
9. Stawicki SP, Grossman MD, Hoey BA et al: Rib fractures in the elderly: a marker of injury severity. *J Am Geriatr Soc*, 2004; 52: 805–8
10. Malghem J, Vande Berg B, Lecouvet F et al: Costal cartilage fractures as revealed on CT and sonography. *AJR Am J Roentgenol*, 2001; 176: 429–32